

INTRAOPERATIVE MOTOR EVOKED POTENTIALS MONITORING IN SPINAL NEUROSURGERY

B. CIONI, M. MEGLIO AND G.F. ROSSI

Istituto di Neurochirurgia, Università Cattolica, Lg. A. Gemelli 8, 00168 Roma, Italy

INTRODUCTION

Technologies originally developed for experimental research are nowadays largely utilized for clinical neurophysiological investigations. The possibility they provide to detect presence, location and characters of functional disorder both at cerebral and at peripheral levels of the nervous system proved to be of paramount importance in neurosurgery: surgical treatment of the epilepsies and of peripheral nerve diseases are probably the best known examples. Equally important is the possibility to previously define during surgery the spatial arrangement of neuronal aggregation and of pathways subserving specific functions, as for instance the cortical motor area or the pyramidal tract: the risk of their damage because of surgical manipulation is thus remarkably reduced. The relatively recent development of noninvasive means of electrophysiological exploration of cerebral and spinal cord structures contributed to expand their utilization.

The intraoperative monitoring (IOM) of somatosensory evoked potentials (SEPs) is the best known and largely utilized of these techniques. It has been used for almost two decades during spinal surgery (24). From a large multicenter study on 51263 patients submitted to surgical treatment of scoliosis it resulted that SEPs monitoring was able to decrease the rate of paraplegia by 60% (25). However, postoperative motor deficits have been reported in spite of unchanged intraoperative SEPs (18, 21, 25, 36). Furthermore, in our experience, during surgery for spinal tumors or vascular malformations, baseline SEPs may be absent or of very poor quality in up to 30% of the patients (7, 8) and, in intramedullary tumor surgery, SEPs may disappear following the posterior myelotomy necessary to approach the tumor (7, 10). In all these cases the operation would be unmonitorable, using SEPs alone. That prompted the development of several techniques to monitor the activity of the cortico-spinal motor system. In 1870 Fritsch and Hitzig first described the electrical excitability of cerebral motor cortex in dogs (12). In 1937 Penfield and Boldrey used electrical stimulation of the exposed human brain to map the motor "homunculus" (31). In 1954 Gualtierotti and Paterson first performed the electrical stimulation of the unexposed brain in baboons and humans through the scalp (13); however the stimulation was too painful to be used clinically. It was only in 1980 that transcranial motor cortex electrical stimulation became available for clinical use: that was due to the introduction of a high voltage, low output impedance electrical stimulator (20). With such a modality of stimulation, Merton and Morton succeeded in activating the motor cortex through the scalp and in recording the

evoked compound muscle action potentials (CMAPs) from limb muscles (20). Since then, many methodological improvements were introduced, including some related to the anesthesiological modalities (5, 8, 11, 15, 17, 29, 30, 34, 35).

The intraoperative electrophysiological monitoring of the functional motor system has to be regarded as one of the safest and precious neurophysiological procedures for assisting the neurosurgeon. For these reasons we thought it useful to review here its most relevant technical aspects and to discuss advantages and limits of its application, as based mainly on the interpretation of the personal results obtained.

METHODS

The proper stimulation of the motor system at cerebral and spinal levels elicits an electrical response which can be recorded from the caudally located components of the motor pathway (motor evoked response or MEPs).

Stimulation

It can be performed at cortical, brain stem and spinal cord levels.

1) Motor cortex stimulation can be performed with transcranial as well as direct modalities.

For transcranial stimulation with electric pulses we utilize corkscrew electrodes (N-spiral electrodes, Nicolet). They are fixed to the scalp, with the anode (active) positioned at CZ or C3 or C4 and the cathode (reference) at FZ or C4 or C3 (according to the 10-20EEG International System). Single square wave pulses of 0.5 ms, 1 c/s, up to 100 mA, or short trains of 3-7 impulses, 0.5 ms, 250-500 c/s, up to 100 mA, at 0.5-2 trains/s, are delivered through a conventional stimulator (Nicolet, Viking IV). We choose the electrode array and the stimulation parameters that allow to record the best response with the lowest current quantity. An alternative modality of transcranial stimulation is the magnetic one. However, in the operating room, it has no advantages over the electrical stimulation. In fact, the effective stimulus is electrical with both techniques; magnetic stimulation requires a coil to be held in place; the coil heats up when repeated stimuli are delivered for hours for continuous monitoring; finally, the painful discomfort produced by electrical stimulation is not a problem in anesthetized patients. The intraoperative transcranial stimulation of the motor cortex is utilized mainly during surgical approaches to the brain stem and spinal levels to monitor the activity of the pyramidal tract.

The direct stimulation is performed with surface electrodes, obviously requiring adequate surgical exposure of the cerebral cortex: grid or strip multielectrodes are employed. The parameters of stimulation are the same as for transcranial electrical stimulation; only the amplitude required is smaller (up to 20mA). It finds its main application when detailed cortical mapping is required to guide local surgical procedures (6).

2) The brainstem stimulation has the purpose to locate the corticospinal tract during surgical approaches to brain stem pathologies. It is performed with surface or depth electrodes directly applied after surgical exposure. We use electrical square waves 0.2 ms duration, 2 mA amplitude, delivered at 1 c/s.

3) Spinal cord stimulation is commonly performed with epidural leads (32, 33); more rarely with electrodes inserted into the spinous processes (26, 27) or in the ligamentum flavum (23). The electrodes are placed rostrally to the spinal cord level harbouring the pathology to be treated surgically. The most commonly utilized parameters for epidural spinal stimulation are 0.3 ms, 3 to 10 mA, up to 50 Hz (32). The evoked response is recorded by caudally placed similar spinal electrodes, or from the peripheral nerves, or from the muscles. The main disadvantage of this relatively non invasive procedure is the simultaneous activation of corticospinal tracts and dorsal columns, orthodromically as well as antidromically; furthermore, dorsal roots and mixed peripheral nerves may be antidromically activated. It follows that the potential evoked by spinal cord stimulation with these techniques cannot be safely regarded as the result of the activation of the corticospinal tract alone.

Recording

MEPs are recorded from the spinal epidural space, peripheral nerves and limb muscles.

Spinal recording (D- or direct waves). It is performed epidurally. We use a lead (diameter 1.27 mm) carrying four in-line cylindric electrodes made of platinum-iridium, with a length of 3 mm each, spaced by 6 mm, for a total length of 30 mm (Quad 3487A, Medtronic). The lead is introduced epidurally over the spinal cord, caudally to the laminectomy performed to surgical treat the spinal pathology. Four to 10 responses to single stimuli applied to the motor cortex are recorded (filter settings of 5-5000 Hz and an epoch length of 20-50 ms) and averaged (Nicolet, Viking IV); single responses may be recorded as well. A second rostral epidural spinal electrode would permit to integrate the MEPs with SEPs evoked by a distal sensory stimulation; it is utilized as well to check the effectiveness of the motor cortex stimulation and changes of the MEP not directly related to surgery.

Muscle recording. Double or multiple stimuli, applied to any part of the intra-axial motor pathway, are required for the study of the response evoked at muscular level (CMAP). Needle electrodes bilaterally placed into the belly of Thenar or Tibialis Anterior muscles are utilized. Five to 10 responses are averaged with a bandpass of 2-200 Hz, and a time base of 200 ms.

Recording of MEPs from peripheral nerves was introduced by Owen et al. (27) to permit the use of muscle relaxant, not compatible with CMAPs recording.

Anesthesia

In our protocol, anesthesia is induced with Propofol (2 mg/kg i.v.) and Fentanyl (2 µg/kg i.v) and maintained with a continuous i.v. infusion of the same drugs (respectively 5-8 mg/kg/hour and 1-1.5 µg/kg/hour); intravenous boli are avoided.

Muscle relaxation for intubation is obtained with Veracurionium Bromide (0.8 mg i.v.). No muscle relaxants are used thereafter. The patient is ventilated with a mixture of Oxygen and Nitrous Oxide below 50%. Oxygen saturation is 98-99%. A temperature probe is inserted into the nasofarinx and body temperature is constantly at 36-37°C. Normotension is rigorously maintained throughout the surgery. Some Authors use muscle relaxation when recording D-waves or peripheral nerves responses (4, 17).

Safety considerations

Only rare and mild collateral effects may follow transcranial motor cortex stimulation, such as transient increase of blood pressure and pulse frequency (10). Seizures are not reported, and even the EEG recorded immediately after the stimulation is normal, if the proper parameters of stimulation described above are utilized (19). A problem might arise from high current density focused on a small surface. Studies of Agnew and McCreery (2) show that no histological changes are present when the charge density at the stimulating electrode is below $40\mu\text{C}/\text{cm}^2/\text{phase}$. The charge density during the peak of transcranial electrical impulse is well below the level found to cause damage.

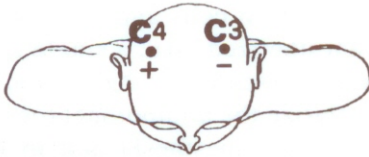PHYSIOLOGY OF MEPS

Patton and Amassian (28) demonstrated that shocks delivered to area 4 in monkeys evoke a series of waves in the ipsilateral pyramid and contralateral corticospinal tract. The first wave was called D or direct wave. The latency of the D-wave was short, suggesting an asynaptic transmission; its persistence after cortex ablation and intracellular recording suggested its origin from excitation of the pyramidal axons. The subsequent waves were called I or indirect waves. The periods between successive I waves were ascribed to single delays for synaptic transmission. The I waves disappeared after cortex ablation, suggesting that they are transynaptically generated. In humans, electrical stimulation of the motor cortex (0.5 ms, 1 c/s, up to 100 mA) evokes at spinal level a first wave with a latency consistent with fast conduction in an asynaptic tract. The recovery curve after double stimulus confirms the asynaptic transmission. This first response is named D-wave for analogy with the monkey response. It represents the activity of fast conducting corticospinal fibers, evoked by the stimulation of the axons of the cortical motoneurons. The stronger the stimulation, the deeper the site of activation along the cortico-spinal tract axons, as demonstrated by the shorter latency of the spinal response (Fig 1). This wave, being transmitted through an asynaptic pathway, is highly resistant to anesthetics. In man, like in monkeys, the D-wave may be followed by I-waves, generated by transynaptic activation of cortical motoneurons. I waves are highly sensitive to anesthesia, due to their transynaptic origin. Consequently, D-waves are best suited for IOM. Their peak to peak amplitude reflects the number of activated fast conducting corticospinal fibers, and therefore is considered the main parameter to be monitored.

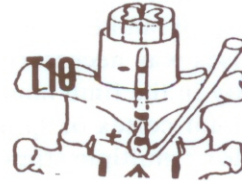INTRAOPERATIVE MONITORING

CORTICO-SPINAL TRACT MONITORING

Stimulation:



Recording:



EFFECT OF DIFFERENT STIMULUS INTENSITY

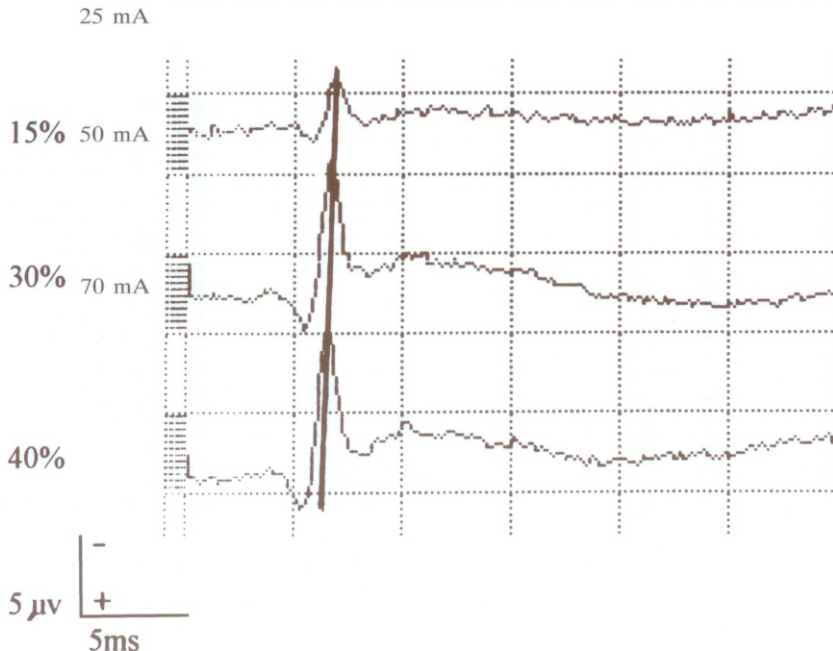


Fig. 1. - Transcranial electrical stimulation of the motor cortex (0.5ms, 1c/s) and recording of the descending corticospinal volley from the Th10 epidural space (averaging of 10 responses).

Effect of increasing stimulus intensity. An increase of amplitude of the response is evident until a maximal amplitude is reached. A decrease of peak latency follows each stimulus intensity increase. The stronger the stimulation, the deeper the site of excitation of pyramidal cells axons, the shorter the latency of the spinal D-wave.

The muscular response to cortical and spinal stimulation (CMAP) is due to the activation of fast corticospinal fibers, alpha-motoneurons and muscle endplates. Temporal and spatial summation of different types of inputs is necessary to produce firing of the alpha-motorneurons: segmentally excitatory and inhibitory inputs, suprasegmental inputs from corticospinal and extrapyramidal fibers, presynaptic inhibiting inputs from both segmental and suprasegmental sites. Adrian and Moruzzi (1) and Brookhart (3) showed that, in anesthetized monkeys and cats, a single pyramidal tract volley does not produce EMG evoked activity: a train of impulses was necessary to depolarize the anterior horn cells and to evoke EMG activity in the limb muscles. Likewise, in the anesthetized man, a single shock to the motor cortex or spinal cord will not evoke any response in the limb muscles; double or multiple stimuli are necessary to depolarize the alfa-motoneurons and to evoke it. The muscle response is very sensitive to anesthesia and to muscle relaxants. The necessity of temporal summation of excitatory cortico-spinal inputs (35) and the influence of anesthesia may explain the high variability both in amplitude and latency showed by these potentials from trial to trial (Fig 2). Consequently, only presence or absence of the muscle response are the parameters utilized for IOM.

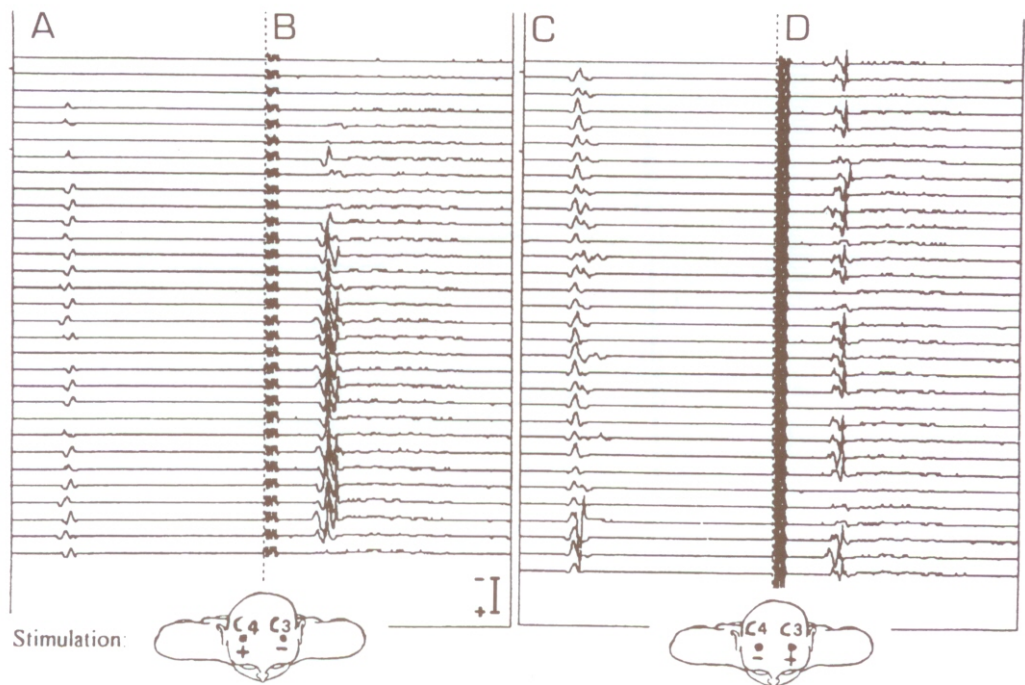


Fig. 2. - Transcranial electrical stimulation of the motor cortex (trains of 5 stimuli, with ISI of 2 ms, 0.5 ms, 100 mA, 2 trains/s), and recordings of the evoked muscle responses from right (A and C) and left (B and D) Tibialis Anterior following single consecutive trains of stimuli.

Note the great variability of the muscle response from trial to trial.

INTRAOPERATIVE MONITORING OF MEPS

Intraoperative monitoring of evoked potentials is based on the assumption that the evoked response reflects the functional status of the activated pathways. The ideal technique for monitoring a neural pathway should have high sensitivity and specificity, should provide real-time update and should not be prone to artifactual aspecific changes.

The spinal epidurally recorded D-waves presents the following advantages: they are stable and robust potentials; they can be updated every 1-10 seconds; full muscle relaxation can be used, avoiding the muscle twitches related to the transcranial motor stimulation; their deterioration is generally progressive, thus leaving time for modification of the surgical strategy. On the other hand, they present disadvantages: they cannot be recorded below Th11; they cannot identify unilateral damage or a damage involving a single extremity. The advantages of CMAPs are: the possibility to monitor the entire motor pathway from the cortex to the muscle and to detect unilateral damages. The disadvantages are: sensitivity to anesthesia and muscle relaxant, variability of the response over time, presence of muscle twitching which may interfere with surgery. The recording from peripheral nerves has the same advantages of CMAPs recording and permits to use muscle relaxants; however, the recorded electrophysiological response is of small amplitude and has an high variability. For what above, we fully agree with Deletis statement: "The combination of these two techniques (D-waves and CMAPs) in the intraoperative monitoring of motor pathways utilized beneficial features of each, while compensating for the disadvantages. The technological advantages in instrumentation and the ability to rapidly alternate between the two techniques has provided so far the most powerful approach to the intraoperative monitoring of the motor pathways. They fulfill very desirable criteria established in the intraoperative neurophysiology, such as specificity, sensitivity, simplicity and speed" (11).

Obviously, the value of neurophysiological monitoring during surgery can be increased by integrating the MEPs analysis with that of the SEPs. A multimodality monitoring tailored to each patient on the basis of the level of surgery, of the preoperative neurological status, and of the specific function of the nervous pathways put at risk by that particular operation, would provide the best opportunities to correct the surgical procedure. Furthermore, the quick detection of aspecific changes of the potentials, not due to surgery, would help in revealing systemic or anesthesiological problems. For surgery at cervical and thoracic level above Th11 monitoring of MEPs (both D-waves and CMAPs) should be integrated by that of SEPs (from median or tibial nerves stimulation). For lesions below Th11, the MEPs monitored with muscle recordings should be integrated with that of SEPs from tibial nerves. In surgical procedures involving the conus medullaris and cauda equina, monitoring of cauda roots and of pudendal function should be added. Finally, mapping of cauda roots is of great help in identifying nervous structures and tumoral or fibrotic tissue.

IOM has to fulfill a fourfold purpose in order to be of clinical usefulness: 1) to

prevent surgically induced neurological deficits through "warning signals"; 2) to make a reliable surgical prognosis; 3) to allow the surgeon to be more radical in his resection; 4) to correct and to improve the surgical strategy. The intraoperative monitoring of MEPs permits to reach these goals.

1) The occurrence of deterioration of the potentials, particularly when is stepwise, has to be considered as a "warning signal" of risk of nervous damaging. In such cases the surgeon changes the surgical strategy, when possible. The recovery of the potentials following the surgeon adjustments, together with the absence of permanent postoperative neurological deficits, is the proof of the effectiveness of IOM in preventing postoperative neurological deficit. The amplitude of the D-wave, which - as mentioned above - correlates with the number of activated cortico-spinal tract axons, in one of the most reliable warning signal. Nagle et al. (23) reviewed 116 cases of spinal and spinal cord surgery monitored using both MEPs and SEPs. Deterioration of the potentials occurred in 8 cases, and in 4 of them this led to change the surgical strategy. At 3 months of follow up, 3 of these patients were ambulatory; 1 died of intercurrent illness. Morota et al. (22) reported on 32 consecutive intramedullary spinal cord tumors operated on with the assistance of MEPs monitoring (D-waves); 13 patients (40%) resulted unmonitorable. In 50% of the monitored patients (10 patients), they observed a decrease in amplitude (30% or greater) of D-waves. Surgery was halted and irrigation of the wound performed, waiting a few minutes for recovery of the potentials. Only in 3 patients the amplitude decrease persisted until the end of the procedure. In our series of 38 spinal cord surgeries assisted by MEPs, and integrated by SEPs monitoring, 4 patients (10.5%) turned out to be unmonitorable because of absent MEPs and SEPs. MEPs deteriorated in 5 cases: in 3 of them the drop in amplitude was permanent, and was always associated with a postoperative motor deficit; in the other 2 cases, a decrease of MEPs amplitude appeared during cervical fusion when hammering the interbody cage; the amplitude returned to normal a few minutes after the end of the fusion. Guerit (14) made a similar observation of SEPs alteration during spinal hammering for scoliosis; he ascribed it to a cord concussion mechanism and he warned against long period of spinal hammering.

2) An outstanding paper on the role of IOM during intramedullary tumor surgery was published by Kothbauer et al. (16). The Authors reviewed 160 personal procedures monitored using MEPs (spinal D-waves and CMEPs) integrated by SEPs. SEPs correlated with postoperative sensory status, particularly joint position sense but "they cannot serve as a monitoring parameters for motor function". The strict correlation between MEPs and postoperative motor function is confirmed by our personal experience: unchanged epidural MEPs are always associated with postoperative preserved neurological function in all the patients; a reduction in amplitude of epidural MEPs, even if combined with preserved muscle MEPs, is followed by postoperative temporary paresis; loss of muscle MEPs correlates with immediate postoperative paraplegia in most cases, but recovery is possible if epidural MEPs are preserved.

3) The role of IOM appears relevant to help the surgeon to proceed without

undue haste, and to guide him in deciding the extension of a tumor resection or correction of scoliosis. That is well exemplified by one of our cases, a 20 year old woman who was sent to us because of a C3-C7 intramedullary tumor. At surgery, a small piece of the caudal pole of the tumor was resected for frozen section for quick histological examination: a diagnosis of malignant astrocytoma was suggested. In spite of that, the MEPs being still normal, the surgeon proceeded to the gradual resection of the tumour. The stability of the MEPs permitted to comfortably continue the surgical procedure and reach the complete tumour resection (Fig. 3). The definitive histological diagnosis was ependimoma. Without IOM, the

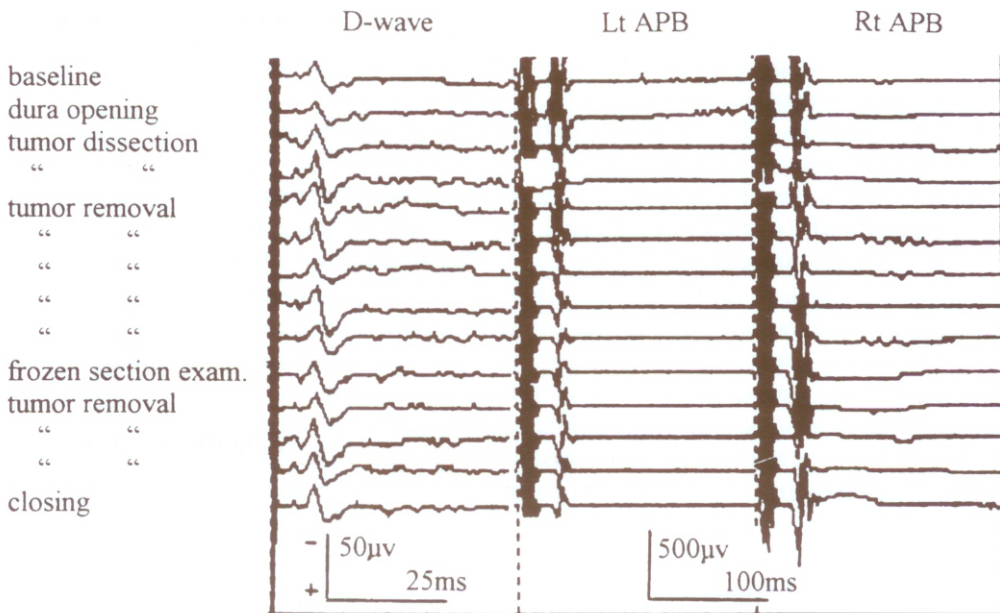


Fig. 3. - Intraoperative MEPs monitoring in a patients with a Cv3-Cv7 intramedullary ependimoma.

D-waves evoked by transcranial electrical stimulation using the single stimulus technique (C3+C4-, 0.5ms, 70mA 1c/s; 10 responses were averaged) are recorded at Th3 epidural level. Muscle responses from left and right Adductor Pollicis Brevis (APB) are evoked by trains of 5 stimuli (ISI 2ms, 0.5ms, 98mA, 1train/s, averaging of 10 responses). The stability of the potentials allowed a radical removal of the tumor.

frozen section examination would have halted further surgery and the patient would have required a second surgical procedure to complete tumor resection after the definitive histological diagnosis.

4) IOM is an important learning experience. Indeed, the changes of the potentials occurring during surgery permit to relate a certain surgical manoeuvre with nervous damage, and consequently to make it easier the understanding of the mecha-

nisms of damage. The surgeon can therefore identify which strategies are more likely to cause damage and consequently improve gesture ergonomics.

CONCLUSIONS

We believe that nowadays IOM must be routine during spinal surgery. This is already largely accepted in the U.S.A. where spinal surgery without the assistance of IOM is considered below the national standard. The intraoperative monitoring of MEPs is a reliable technique with high sensitivity and specificity. However, it has some limitations. In our experience 10% of the patients are unmonitorable, because of absent potentials (6, 7). Morota et al. (22) reported that about one third of intramedullary spinal cord tumors are unmonitorable. Muscle MEPs from lower extremities are sometimes difficult to evoke: this prevents monitoring in patients with lesions below TH10 or in patients with unrecordable D-waves because of desynchronization of the cortico-spinal descending volley. A method to enhance alfa motoneurons excitability under general anesthesia would be of great help. Monitoring of SEPs in addition to that of MEPs is certainly advisable. The recognition of spinal pathways or, more generally, of functional nervous tissue from foreign tissue, such as tumoral tissue, through electrophysiological mapping is also a technique to be developed. Further progress in the interpretation of the many and complex neural events set in motion by the delivery of electrical pulses to the nervous system would improve both the methodology and the evaluation of its results. Most of what we know at this regard comes from the experimental research in animals. The presently largely available application of the neurophysiological means of investigation to neurosurgical patients, such as the intraoperative monitoring of motor evoked potentials described above, might provide a good opportunity to reach a better knowledge of the functional organization of the much more complex brain and spinal cord of the human being.

SUMMARY

Neurological damage may follow even a technically accurate spinal surgery. The intraoperative monitoring of neurological functions put at risk by the operation is a method utilized to correctly identify the topography of neural structures and to avoid surgical insults. SEPs monitoring is 20 year old, and only recently direct motor tract monitoring has become possible. Transcranial electrical motor cortex stimulation with single pulses or with short trains of stimuli and recording of the evoked responses from the spinal epidural space (D-waves) and from limb muscles is a reliable and safe technique for monitoring corticospinal tract activity even under general anesthesia. The method has a solid theoretical experimental background. Its clinical application has demonstrated high sensitivity and specificity. Intraoperative MEPs monitoring is nowadays considered indispensable during spinal neurosurgery.

REFERENCES

1. ADRIAN, E.D. AND MORUZZI, G. Impulses in the pyramidal tract. *J. Physiol., Lond.*, **97**: 153-199, 1939.
2. AGNEW, W.F. AND MCCREERY, D.B. Considerations for safety in the use of extracranial stimulation for motor evoked potentials. *Neurosurgery*, **20**: 143-147, 1987.
3. BROOKHART, J.M. The study of corticospinal activation of motorneurons. *Res. Publ. Ass. Res. Nerv. Ment. Dis.*, **30**: 157-163, 1952.
4. BURKE, D., HICKS, R., STEPHEN, J., WOODFORTH, I. AND CRAWFORD, M. Assessment of corticospinal and somatosensory conduction simultaneously during scoliosis surgery. *EEG Clin. Neurophysiol.*, **85**: 388-96, 1992.
5. BURKE, D. AND HICKS, R.G. Surgical monitoring of motor pathways. *J. Clin. Neurophysiol.*, **15**: 194-205, 1998.
6. CEDZICH, C., TANIGUCHI, M., SCHAFER, S. AND SCHRAMM, J. Somatosensory evoked potential phase reversal and direct motor cortex stimulation during surgery in and around the central region. *Neurosurgery*, **38**: 962-970, 1996.
7. CIONI, B., MEGLIO, M., CABEZAS CUEVAS, D., TAMBURRINI, G., VISOCCHI, M. AND FIORE, G. Multimodal intraoperative neurophysiological monitoring in vertebrospinal surgery. *Riv. Neurobiologia*, **43**: 549-553, 1997.
8. CIONI, B., MEGLIO, M., CABEZAS CUEVAS, D., VISOCCHI, M. AND PEROTTI, V. Somatosensory and cortico-spinal tract monitoring during spinal cord surgery. Pp. 421-425. In: STALBERG, E.V., DE WEERD, A.W. AND ZIDAR, J. (Eds.), *Neurophysiology ECCN 98*. Bologna, Monduzzi, 1998.
9. DELETIS, V. Intraoperative monitoring of the functional integrity of the motor pathways. Pp 201-214. In: Dervinsky, O., BERIC, A. AND DOGALI M. (Eds.), *Electric and Magnetic Stimulation of the Brain and Spinal Cord*. New York, Raven Press, 1993.
10. DELETIS, V. Evoked potentials. Pp 288-315. In: LAKE, C.L. (Ed.), *Clinical Monitoring for Anesthesia and Critical Care*. Philadelphia, Saunders Co, 1994.
11. DELETIS, V. Intraoperative neurophysiology of the motor system of the spinal cord. Pp 391-398. In: STALBERG, E.V., DE WEERD, A.W. AND ZIDAR, J. (Eds.), *Neurophysiology ECCN 98*. Bologna, Monduzzi, 1998.
12. FRITSCH, G. AND HITZIG, E. Ueber die elektrische Erregbarkeit des Grosshirns. *Archs Anat. Physiol. Wiss. Med.*, **37**: 300-322, 1870.
13. GUALTIEROTTI, T. AND PATTERSON, A.S. Electrical stimulation of the unexposed cerebral cortex. *J. Physiol., Lond.*, **125**: 278-291, 1954.
14. GUERIT, J.M. Neuromonitoring in the operating room: why, when and how to monitor? *EEG Clin. Neurophysiol.*, **106**: 1-21, 1998.
15. JONES, S.J. HARRISON, R., KOH, K.F., MENDOZA, N. AND CROCKARD, H.A. Motor evoked potential monitoring during spinal surgery: responses of distal limb muscles to transcranial cortical stimulation with pulse trains. *EEG Clin. Neurophysiol.*, **100**: 375-383, 1996.
16. KOTHBAUER, K., DELETIS, V. AND EPSTEIN, F.J. Intraoperative spinal cord monitoring for intramedullary surgery: an essential adjunct. *Pediatr. Neurosurg.*, **26**: 247-254, 1997.
17. LANG, E.W., BEUTLER, A.S., CHESNUT, F.M., PATEL, P.M., KENNELLY, N.A., KALKMAN, C.J., DRUMMOND, J.C. AND GARFIN, S.R. Myogenic motor-evoked potential monitoring using partial neuromuscular blockade in surgery of the spine. *Spine*, **21**: 1676-1686, 1996.
18. LESSER, R.P., RAUDZENS, P. AND LUDERS, H. Postoperative neurological deficits may occur despite unchanged intraoperative somatosensory evoked potentials. *Ann. Neurol.*, **19**: 22-25, 1986.
19. LEVY, W.J. Clinical experience with motor and cerebellar evoked potentials monitoring. *Neurosurgery*, **20**: 169-182, 1987.

20. MERTON, P.A. AND MORTON, H.B. Stimulation of the cerebral cortex in the intact human subject. *Nature*, **285**: 227, 1980.
21. MOLAIE, M. False negative intraoperative somatosensory evoked potentials with simultaneous bilateral stimulation. *EEG Clin. Electroencephalogr.*, **17**: 6-19, 1986.
22. MOROTA, N., DELETIS, V., CONSTANTINI, S., KOFLER, M., COHEN, H. AND EPSTEIN, F. The role of motor evoked potentials during surgery for intramedullary spinal cord tumors. *Neurosurgery*, **41**: 1327-1336, 1997.
23. NAGLE, K.J., EMERSON, R.G., ADAMS, D.C., HEYER, E.J., ROYE, D.P., SCHWAB, F.J., WEIDENBAUM, M., MCCORMICK, P., PILE-SPPELLMAN, J., STEIN, B.M., FARCY, J.P., GALLO, E.J., DOWLING, K.C. AND TURNER, C.A. Intraoperative monitoring of motor evoked potentials. A review of 116 cases. *Neurology*, **47**: 999-1094, 1996.
24. NUWER, M.R. Spinal cord monitoring with somatosensory techniques. *J. Clin. Neurophysiol.*, **15**: 183-193, 1998.
25. NUWER, M.R., DAWSON, E.G., CARLSON, L.G., KANIM, L.E.A. AND SHERMAN, J.E. Somatosensory evoked potential spinal cord monitoring reduces neurologic deficits after scoliosis surgery: results of a large multicenter survey. *EEG Clin. Neurophysiol.*, **96**: 6-11, 1995.
26. OWEN, J.H. Intraoperative stimulation of the spinal cord for prevention of spinal cord injury. In: DEVINSKY, O., BERIC, A. AND DOGALI, M. (Eds.). *Electrical and Magnetic Stimulation of the Brain and Spinal Cord*. New York, Raven Press, 1993.
27. OWEN, J.H., BRIDWELL, K.H., GRUBB, R., JENNY, A., ALLEN, B., PADBERG, A.M. AND SHIMON, S.M. The clinical application of neurogenic motor evoked potentials to monitor spinal cord function during surgery. *Spine*, **16**: S285-390, 1991.
28. PATTON, H.D. AND AMASSIAN, V.E. Single and multiple unit analysis of cortical state of pyramidal tract activation. *J. Neurophysiol.*, **17**: 345-363, 1954.
29. PECHSTEIN, U., CEDZICH, C., NADSTAWEK, J. AND SCHRAMM, J. Transcranial high-frequency repetitive electrical stimulation for recording myogenic motor evoked potentials with the patient under general anesthesia. *Neurosurgery*, **39**: 335-344, 1996.
30. PECHSTEIN, U., NADSTAWEK, J., ZENTNER, J. AND SCHRAMM, J. Isoflurane plus nitrous oxide versus propofol for recording of motor evoked potentials after high frequency repetitive electrical stimulation. *EEG Clin. Neurophysiol.*, **108**: 175-181, 1998.
31. PENFIELD, W. AND BOLDREY, E. Somatic motor and sensory representation in the cerebral cortex of man as studied by electrical stimulation. *Brain*, **60**: 389-443, 1937.
32. TAMAKI, T. Spinal cord monitoring with spinal potentials evoked by direct stimulation of the spinal cord. Pp 139-149. In: DESMEDT, J.E. (Ed) *Neuromonitoring in Surgery*, Amsterdam, Elsevier Science Publ., 1989.
33. TAMAKI, T., TAKENO, H. AND NAKAGAWA, T. Evoked spinal cord potential elicited by spinal cord stimulation and its use in spinal cord monitoring. Pp 428-433. In: CRACCO, R.Q. AND BODIS-WOLLNER, I. (Eds.), *Evoked Potentials*, New York, Alan R. Liss, 1988.
34. TANIGUCHI, M., CEDZICH, C. AND SCHRAMM, J. Modification of cortical stimulation for motor evoked potentials under general anesthesia: technical description. *Neurosurgery*, **32**: 219-226, 1993.
35. TAYLOR, B.A., FENNELLY, M.E., TAYLOR, A. AND FARRELL, J. Temporal summation -the key to motor evoked potential spinal cord monitoring in humans. *J. Neurol. Neurosurg. Psychiatry*, **56**: 104-6, 1993.
36. ZORNOW, M.H. AND DRUMMOND, J.C. Intraoperative somatosensory evoked responses recorded during onset of the anterior spinal artery syndrome. *J. Clin. Monit.*, **5**: 243-246, 1989.